

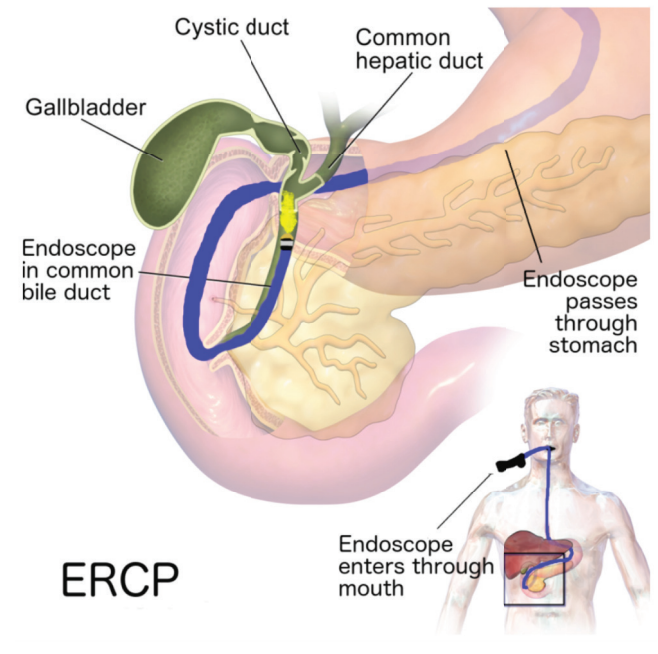
Complex ERCP during the COVID-19 Pandemic.

Tales of expert care.

What is ERCP?

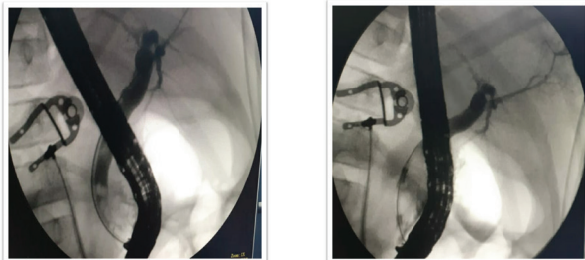
Endoscopic Retrograde Cholangio Pancreatography(ERCP) is used to primarily diagnose conditions of bile duct and main pancreatic duct including stones in CBD, inflammatory strictures, bile leak, and cancer which usually leads to obstructive jaundice.

A couple of patients with obstructive jaundice have been successfully treated during the COVID-19 pandemic by **Dr S Ravikumar**, Surgical Gastroenterologist and Hepatobiliary Surgeon, with the help of Interventional Radiologist, **Dr P Santhosh Kumar**, Kauvery Hospital Salem.



Case #1 : A 6-year old with Common Bile Duct Stones

- The girl presented with typical symptoms of jaundice and abdominal pain. Imaging and diagnosis revealed stones in the common bile duct leading to the symptoms.
- Uncommon in this age-group.
- The child required immediate attention and our experts removed the stones endoscopically via ERCP



Case #2 : A 75-year-old with Periampullary Cancer

- The elderly lady presented with Jaundice
- Imaging and diagnosis revealed Periampullary cancer in the lower bile duct region.
- As growth was large, ERCP alone was difficult
- With combined radiological and ERCP technique(Rendezvous), CBD stenting was done in order to alleviate jaundice.
- The patient was discharged home within 2 days after the symptoms subsided

